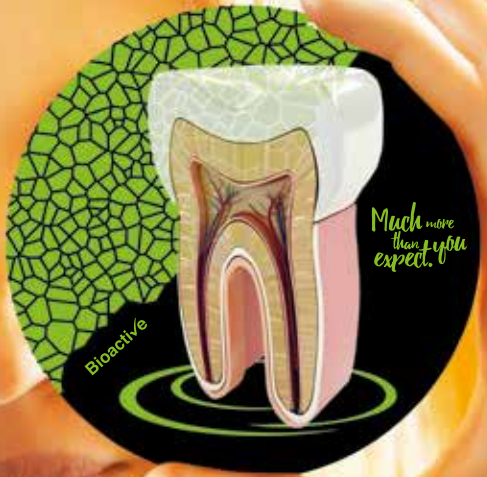



HARVARD[®]



**Clinical cases
of endodontics
with Harvard's
bioactive MTA products.**



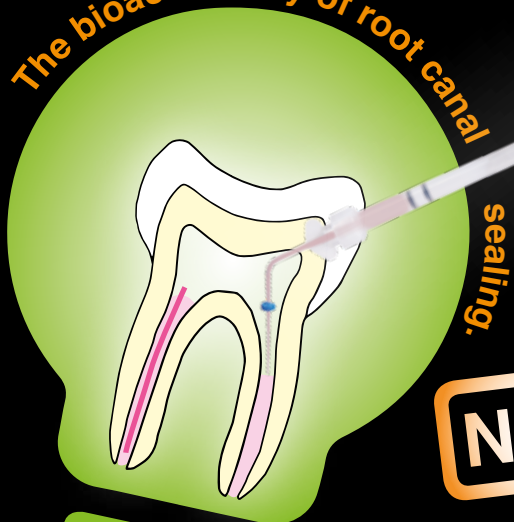EN

Harvard

BioCal[®]-RootSeal

Bioactive, resin-modified MTA root canal sealer

The bioactive way of root canal



sealing.

NEW!



Apatite formation through reaction of released calcium and hydroxide with endogenous phosphate.

- Excellent seal
- Apatite formation through reaction of released calcium and hydroxide with endogenous phosphate
- Mineralizing
- Environment hostile to bacteria (pH 11)
- Self cure and additional light cure for faster setting of the surface
- Easy to remove and revise, e.g. for subsequent post placement with fiber posts
- Convenient application from the minimix syringe
- Radiopaque

Optional: for optimal, bubble-free, direct application into the root canal also available with EndoDirect syringes (Harvard BioCal[®]-RootSeal plus EndoDirect)



“ Best results with Harvard BioCal®-RootSeal. ”

„In various cases, **Harvard BioCal®-RootSeal** has demonstrated that it is a safe and reliable root canal sealer.

I recommend **Harvard BioCal®-RootSeal** to every dental professional because it is easy to use, safe and cost-effective, no matter what technique is used.

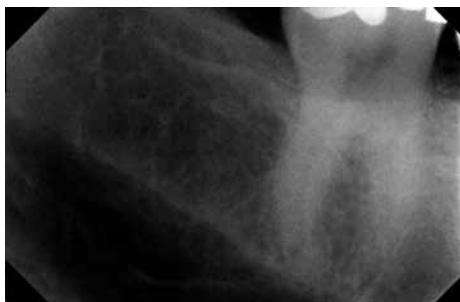Since we started working with **Harvard BioCal®-RootSeal**, we no longer have to fear possible negative consequences of exceeding the material through the apex (foramen apicale).“



All X-ray images courtesy of Dentist Dr. Hababat, Dubai.
Original captions in English;
All product names are registered trademarks of the respective manufacturers.

Dentist Dr. Nihad Hababat,
Dubai

Deep filling near the pulp, tooth 47

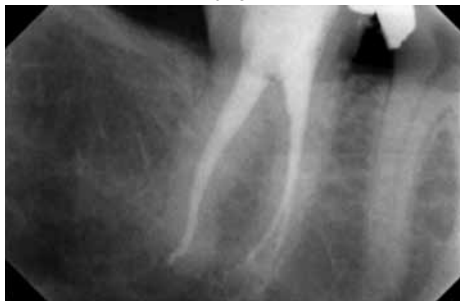

before

The patient came in with severe and constant pain in the right lower molar (tooth 47 / diagnostic pulpitis)

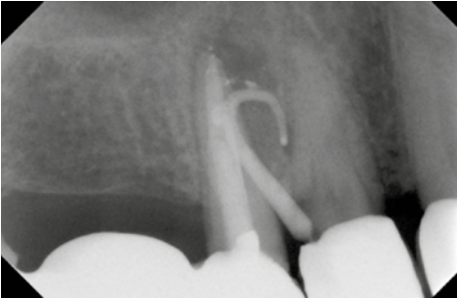
X-ray: Tooth 47 – deep filling near the pulp.

after



X-ray of the final obturation with **Thermafili®** and **Harvard BioCal®-RootSeal**.

Chronic periapical abscess tooth 14

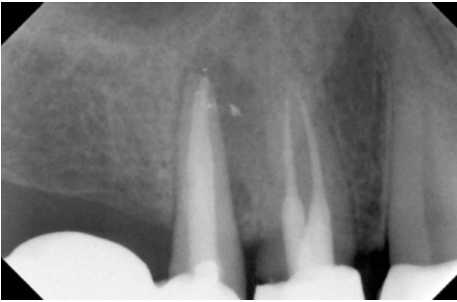


The patient came in with an abscess with fistula formation in the upper right premolar region (tooth 14).

X-ray with inserted gutta-percha point in the fistula tract.

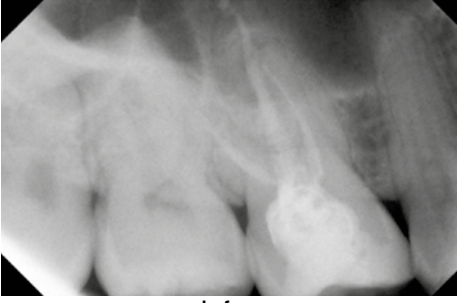
before

after



X-ray of the final obturation with Therafil® and Harvard BioCal®-RootSeal.

Acute periapical periodontitis tooth 16

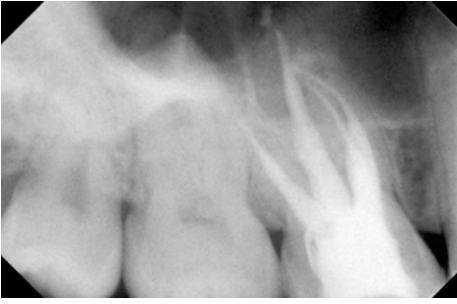

The patient came in with a dull bite pain on the upper right molar (tooth 16).

X-ray image before treatment.

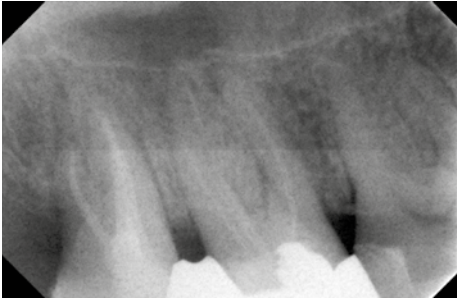
before

after



X-ray of the final obturation with Therafil® and Harvard BioCal®-RootSeal.

Acute periapical periodontitis tooth 17

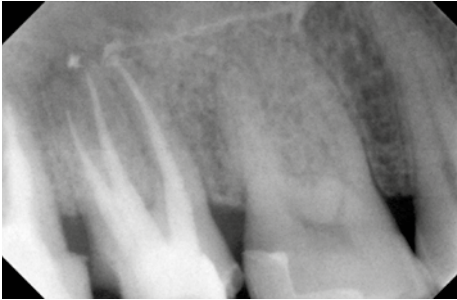


The patient came with pain in the right maxilla in the area of the molars (tooth 17).

X-ray shows root canals at 17 and 18.

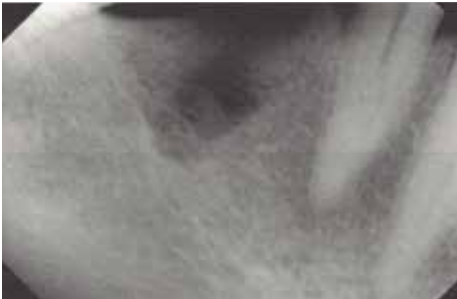before

after



X-ray of the final obturation with Therafil® and Harvard BioCal®-RootSeal.

Acute periapical periodontitis tooth 44

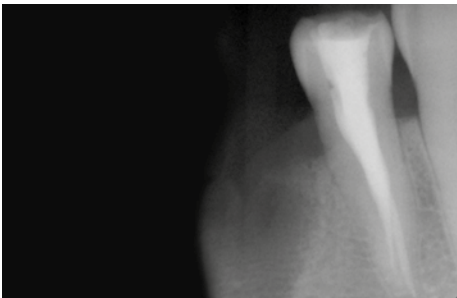


This patient was referred from another clinic. He came to our clinic (Infinity Dental Clinic, Dubai) complaining of pain in the lower right premolar region. (Tooth 44)

First X-ray.

before

after



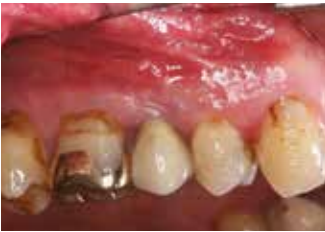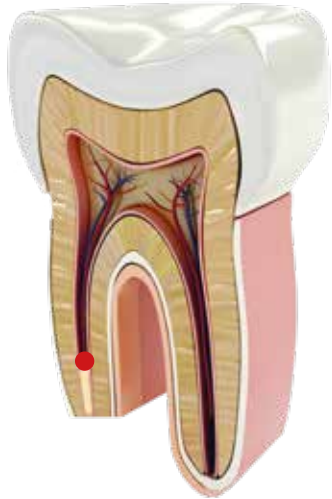
X-ray of the final obturation with Therafil® and Harvard BioCal®-RootSeal.

Harvard MTA-Retro

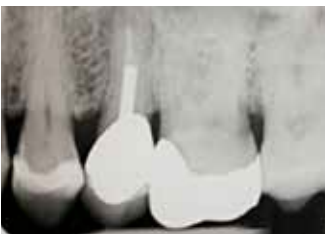Fast setting, extra radiopaque
MTA cement in capsules



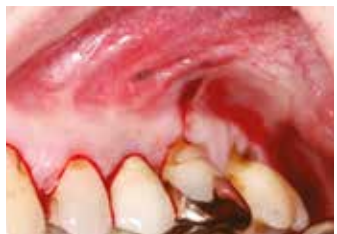- **Specially recommended for root end filling (retrograde)**
- Firm consistency
- Extra radiopaque
- Fast setting
- Mixing time: 30 sec.
- Working time: 2:00 min.
(from start of mixing at 23 °C (73 °F))
- Next clinical step: 3:00 min.
- Set also in humid conditions



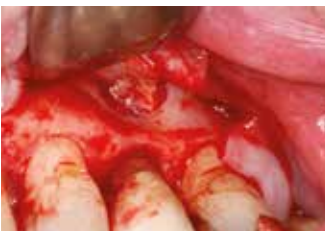1. First clinical image



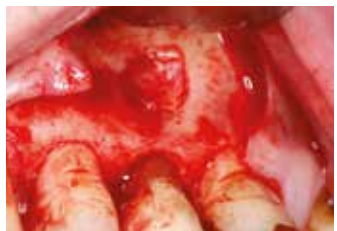2. First X-ray before treatment



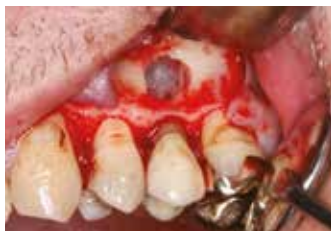3. Incision of the gingiva for flap surgery



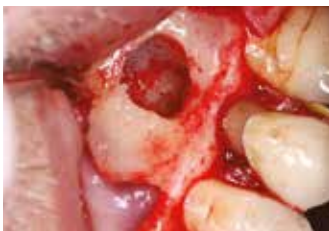4. Retraction of the flap to expose the infected area



5. Exposure of the inflamed area with infected bone tissue



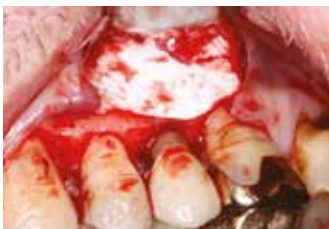6. Removal of infected bone tissue, exposure of the root tip



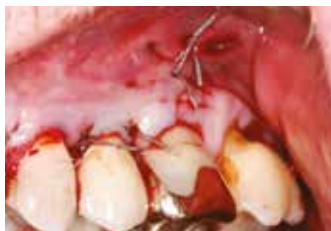7. Resection of the root tip



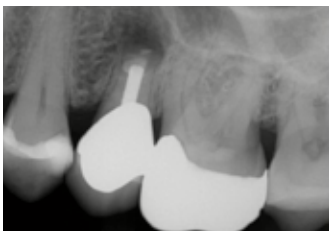8. Dispensation of Harvard MTA-Retro (factory photo)



9. Covered with a membrane after apical placement of Harvard MTA-Retro



10. Closure of the flap with some stitches



11. X-ray after placement of Harvard MTA Retro

“ Harvard MTA Retro. The perfect material for this treatment. ”

Infected tooth 25

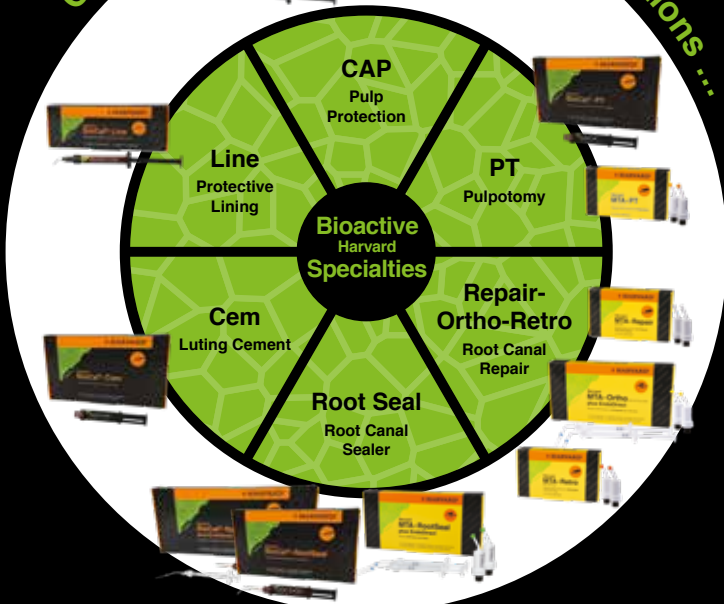„Pain swollen on the upper left second premolar 25. From the diagnostic X-ray, a radiolucency around the tip of the root, clinical examination reveals movement of the tooth and an old root canal with post and core plus crown.“



All treatment photos and x-rays courtesy of Dr. med. Klaus Herrligkoffer, Berlin, Germany

Dentist Dr. med. Klaus Herrligkoffer, Berlin

Overview of the bioactive Harvard solutions ...



Harvard BioCal®-CAP, 1 g syringe, 12 needle tips	7081550
Harvard MTA-CAP, 2 OptiCaps® à 0.25 g in aluminum pouch	7081503
Harvard BioCal®-PT, 2.5 ml minimix syringe, 10 mixing tips	7081556
Harvard MTA-PT, 2 OptiCaps® ea. 0.25 g in aluminum pouch	7081512
Harvard MTA-Repair, 2 OptiCaps® ea. 0.25 g in aluminum pouch	7081505
Harvard MTA-Ortho, 2 OptiCaps® ea. 0.25 g in aluminum pouch, 2 EndoDirect syringes	7081510
Harvard MTA-Retro , 2 OptiCaps® ea. 0.25 g in aluminum pouch	7081506
Harvard BioCal®-RootSeal , 2.5 ml minimix syringe, 15 mixing tips, accessories	7081553
Harvard BioCal®-RootSeal plus EndoDirect	7081552
2.5 ml minimix syringe, 10 EndoDirect syringes, 10 mixing tips	
Harvard MTA-RootSeal, 2 OptiCaps® ea. 0.25 g in aluminum pouch	7081513
Harvard MTA-RootSeal, 2 OptiCaps® ea. 0.25 g in aluminum pouch, 2 EndoDirect	7081511
Harvard BioCal®-Cem, 2.5 ml minimix syringe, 8 mixing tips, 3 intra tips long	7081558
Harvard BioCal®-Line, 1 g syringe, 12 needle tips	7081554

11061_EN_11/21_A
Harvard Dental International GmbH
 Margaretenstr. 2 - 4, 15366 Hoppegarten, Germany
 Tel.: + 49 30/99 28 978-0
 Fax: + 49 30/99 28 978-19
 info@harvard-dental-international.de

www.harvard-dental.de